

doi: 10.3978/j.issn.1000-4432.2020.05.04

View this article at: <http://dx.doi.org/10.3978/j.issn.1000-4432.2020.05.04>

多模式影像技术诊断中心性浆液性脉络膜视网膜病变 并发脉络膜新生血管1例

吴敏, 闵洁, 杨文芝, 盛智超

[云南省第二人民医院眼科(昆明医科大学第四附属医院, 云南省眼科研究所, 云南省眼科疾病研究重点实验室, 云南省姚克专家工作站, 云南省眼科疾病临床医学中心, 云南省眼部疾病临床医学研究中心), 昆明 650021]

[摘要] 中心性浆液性脉络膜视网膜病变(central serous chorioretinopathy, CSC)是临床常见疾病, 近年来CSC合并(choroidal neovascularization, CNV)的病例时有报道, 我们应用多模式影像技术诊断和随访CSC合并CNV病例1例, 讨论多模式影像技术在该病中的应用价值。

[关键词] 中心性浆液性脉络膜视网膜病变; 脉络膜新生血管; 多模式影像技术

Diagnosis of central serous chorioretinopathy complicated with choroidal neovascularization by multi-mode imaging technology: A case report

WU Min, MIN Jie, YANG Wenzhi, SHENG Zhichao

[Department of Ophthalmology, 2nd People's Hospital of Yunnan Province (4th Affiliated Hospital of Kunming Medical University, Yunnan Eye Institute, Key Laboratory of Yunnan Province for the Prevention and Treatment of ophthalmology, Provincial Innovation Team for Cataract and Ocular Fundus Disease, Expert Workstation of Yao Ke, Yunnan Eye Disease Clinical Medical Center, Yunnan Eye Disease Clinical Medical Research Center), Kunming 650021, China]

Abstract Central serous chorioretinopathy (CSC) is a common disease in clinical practice. In recent years, CSC complicated with choroidal neovascularization (CNV) cases have been reported. In this article, we applied multi-mode imaging technology to diagnose and follow up 1 case of CSC complicated with CNV, aiming to discuss the application value of multi-mode imaging technology in the diagnosis of this disease.

Keywords central serous chorioretinopathy; choroidal neovascularization; multi-model image technology

收稿日期 (Date of reception): 2020-04-01

通信作者 (Corresponding author): 吴敏, Email: ynwumin@126.com

基金项目 (Foundation item): 云南省应用基础研究 (昆医联合专项) [2017FE467(-195), 2017FE468(-084)]; 云南省基础研究计划重点项目 (2019FA028); 云南省医学学科带头人培养计划 (D2017-010)。This work was supported by the Applied Basic Research of Yunnan Province (Kunming Medical University Joint Project) [No. 2017FE467(-195), 2017FE468(-084)], Key Project of Applied Basic Research of Yunnan Province (No. 2019FA028), and Yunnan Medical Academic Leader Training Programme (D2017-010), China.

中心性浆液性脉络膜视网膜病变(central serous chorioretinopathy, CSC)是临床上常见的疾病,近年来CSC合并脉络膜新生血管(choroidal neovascularization, CNV)的病例时有报道,我们应用多模式影像技术诊断和随访CSC并发CNV患者1例,现报道如下。

1 临床资料

患者,男,44岁,因体检发现左眼视力下降10 d就诊。既往体健,否认吸烟史和服药史,否认眼部激光治疗史。全身检查无阳性发现。眼部检查:最佳矫正视力(best corrected visual acuity, BCVA): OD 0.9, OS 0.3,眼前节检查正常,玻璃体腔清亮,眼底检查可见左眼黄斑区色素紊乱,中心凹反光消失,黄斑中心凹颞侧可见灰白色病灶(图1)。相干光层析成像术(optical coherence tomography, OCT)检查见左眼黄斑区中心凹下稍偏颞侧高反射病灶,伴少量视网膜下积液(图2),炫彩OCT检查可见左眼黄斑区色彩紊乱和病灶区域略隆起(图3),自发荧光检查发现右眼正常,左眼黄斑区不均匀的自发荧光改变(图4)。眼底荧光血管造影(fundus fluorescence angiography, FFA)检查发现双眼后极部视网膜多灶性斑片状高荧光病灶,左眼黄斑中心凹偏颞侧在造影早期出现渗漏点,随造影时间的推移出现明显的渗漏,造影早期右眼视盘鼻下方见一渗漏点,随时间推移出现

墨渍样渗漏(图4)。为进一步确定渗漏点的性质,我们对该患者进行了眼底相干光层析血管成像术(optical coherence tomography angiography, OCTA)检查,发现右眼正常,左眼浅层、深层毛细血管层面中心凹无血管区(foveal avascular zone, FAZ)颞侧和下方边缘不规则,无血管层面在与FFA渗漏点相对应位置可见新生血管结构(图5)。综合以上多模式影像检查结果,本病例诊断为双眼慢性CSC合并左眼CNV。获取患者知情同意后,予康柏西普注射液(成都康弘药业)0.05 mL左眼玻璃体腔内注射1次。拟对患者右眼进行激光治疗,但与患者沟通病情后,患者认为病情没有影响视力,要求以治疗左眼为主,右眼暂时观察,不做治疗。1个月后复诊,患者自觉左眼视力明显好转,左眼BCVA提升至0.8,眼底检查未见明显变化,OCT检查发现中心凹下偏颞侧高反射病灶缩小,视网膜下积液吸收(图2)。OCTA检查发现左眼浅层、深层毛细血管层面FAZ形状规则程度明显改善,无血管层面新生血管结构缩小(图2)。OCTA图像中CNV病灶采用手动分层,同时用机器自带的去除上方血管投影功能去除来自病灶的血管投影,应用Image J软件定量分析,主要参数包括治疗前后的中心凹旁表层和深层视网膜血管密度、FAZ面积和CNV面积,测量数据见表1。分析结果显示抗血管内皮生长因子(vascular endothelial growth factor, VEGF)治疗后患者左眼黄斑区表层和深层视网膜血管密度增加,FAZ面积扩大,CNV面积明显缩小。

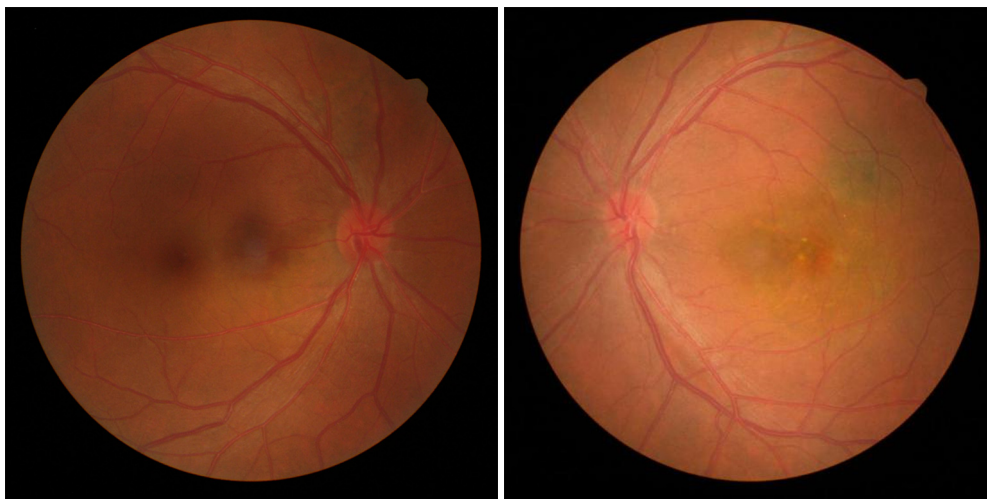


图1 双眼眼底彩照,可见左眼黄斑区色素紊乱,中心凹颞侧可见灰白色病灶

Figure 1 Color fundus photograph: pigment disorder presented in the macular area in left eye, gray-white lesion was seen in the temporal side of the fovea

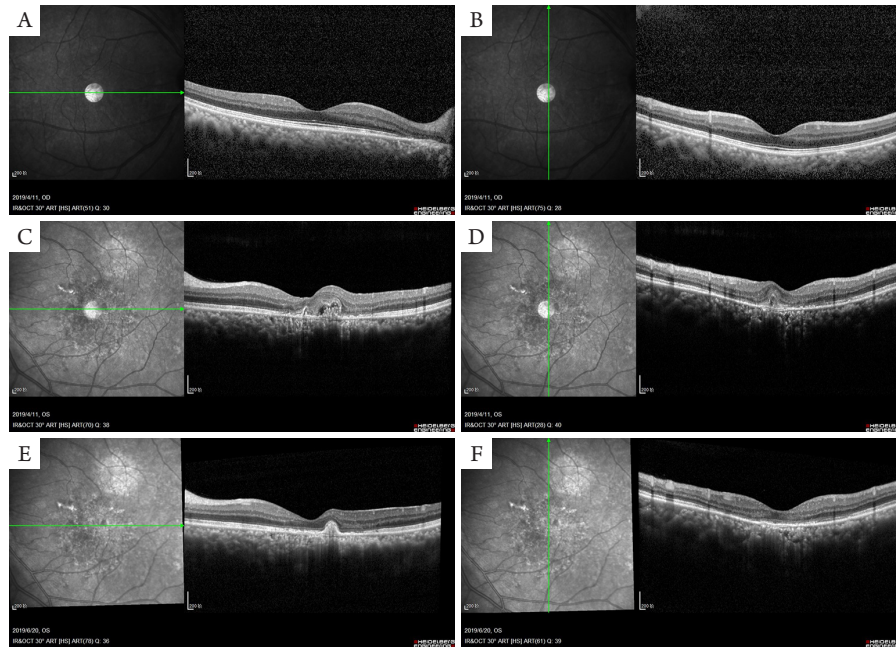
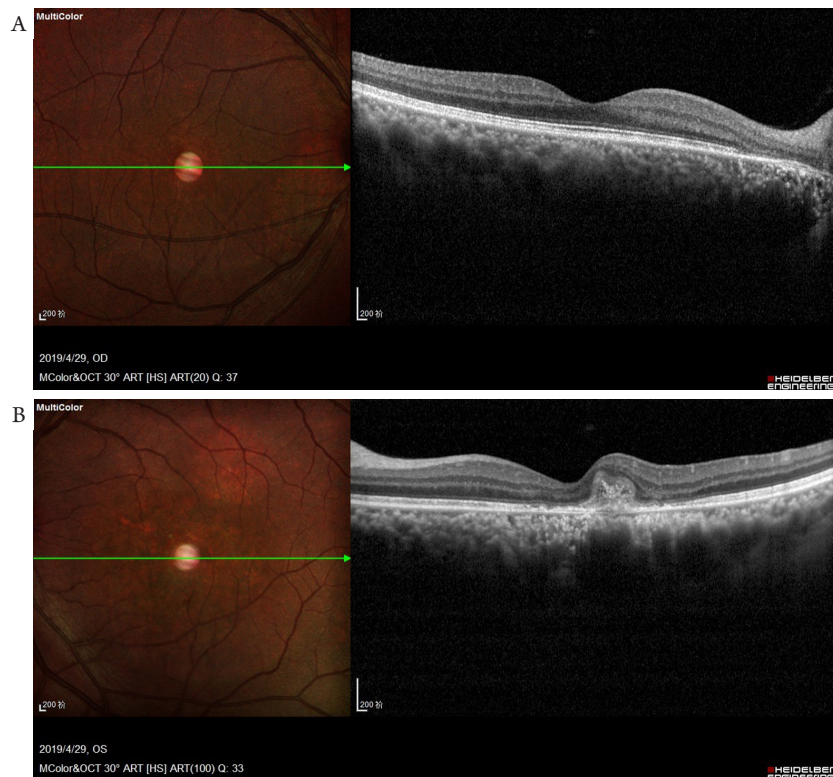


图2 双眼OCT检查

Figure 2 OCT of bilateral eyes

(A, B)治疗前右眼OCT影像; (C, D)治疗前左眼OCT影像, 可见中心凹下稍偏颞侧高反射病灶, 伴少量视网膜下积液; (E, F)治疗后左眼OCT影像, 可见中心凹下偏颞侧高反射病灶缩小, 视网膜下积液吸收。

(A, B) OCT images of the right eye before treatment; (C, D) OCT images of the left eye before treatment. A highly reflective lesion was shown in the temporal side of the fovea with mild subretinal fluid (SRF); (E, F) OCT images of the left eye after treatment. A highly reflective lesion in the temporal side shrank with absorption of SRF.



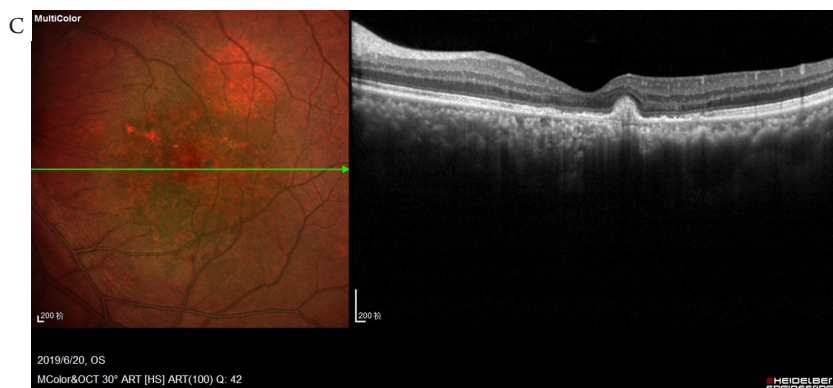


图3 双眼炫彩OCT

Figure 3 Multicolor OCT images in bilateral eyes

(A)右眼炫彩OCT; (B)治疗前左眼炫彩OCT, 可见黄斑区色彩紊乱和中心凹颞侧区域不规则隆起; (C)治疗后左眼炫彩OCT, 可见黄斑区色彩紊乱, 中心凹颞侧区域病灶显著缩小。

(A) Multicolor OCT images of the right eye; (B) Multicolor OCT images of the left eye before treatment. Color disorders in macular area and irregular lesion in the temporal side of the fovea were shown; (C) Multicolor OCT images of the left eye after treatment. Color disorders in macular area and the significant shrinkage of the lesion were shown.

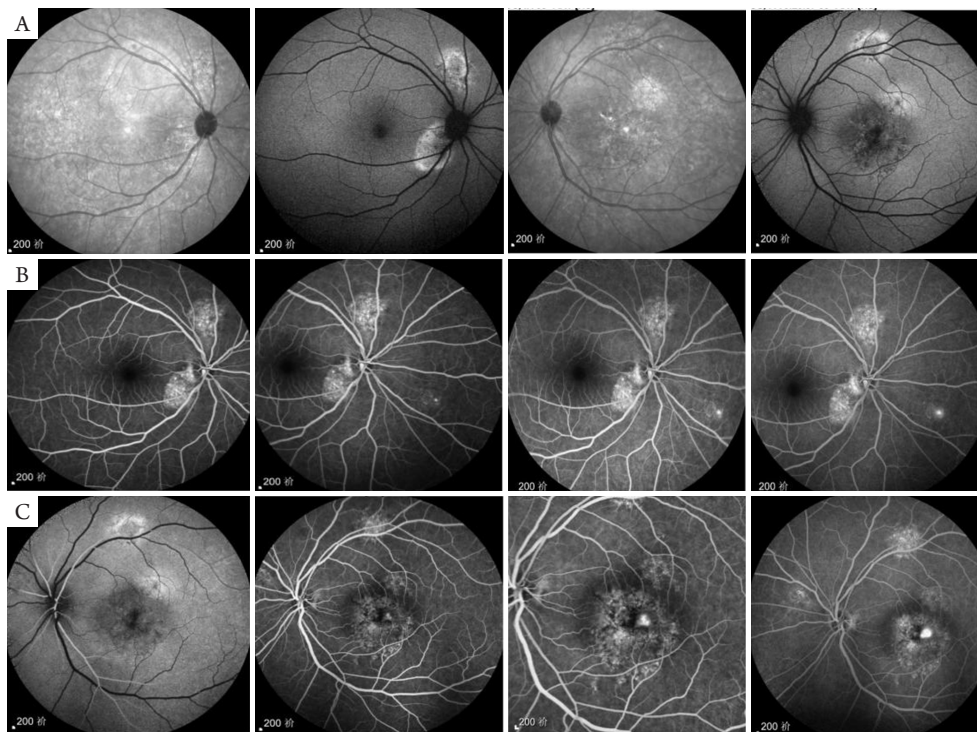


图4 自发荧光和眼底荧光血管造影

Figure 4 Images of autofluorescence and FFA

(A)双眼自发荧光, 可见左眼黄斑区不均匀的自发荧光改变; (B)右眼FFA图像, 造影早期右眼视盘鼻下方见一渗漏点, 随时间推移出现墨渍样渗漏; (C)左眼FFA图像, 黄斑中心凹偏颞侧在造影早期出现渗漏点, 随造影时间的推移出现明显的渗漏。

(A) Bilateral images of autofluorescence. Uneven autofluorescence presented in the left macular area; (B) FFA images of the right eye. A leaking point was observed in the inferior nasal side to optic disc in the early stage and ink-like leakage was seen over time; (C) FFA images of the left eye. A leaking point was noted in the temporal side to the fovea and evident leakage was seen over time.

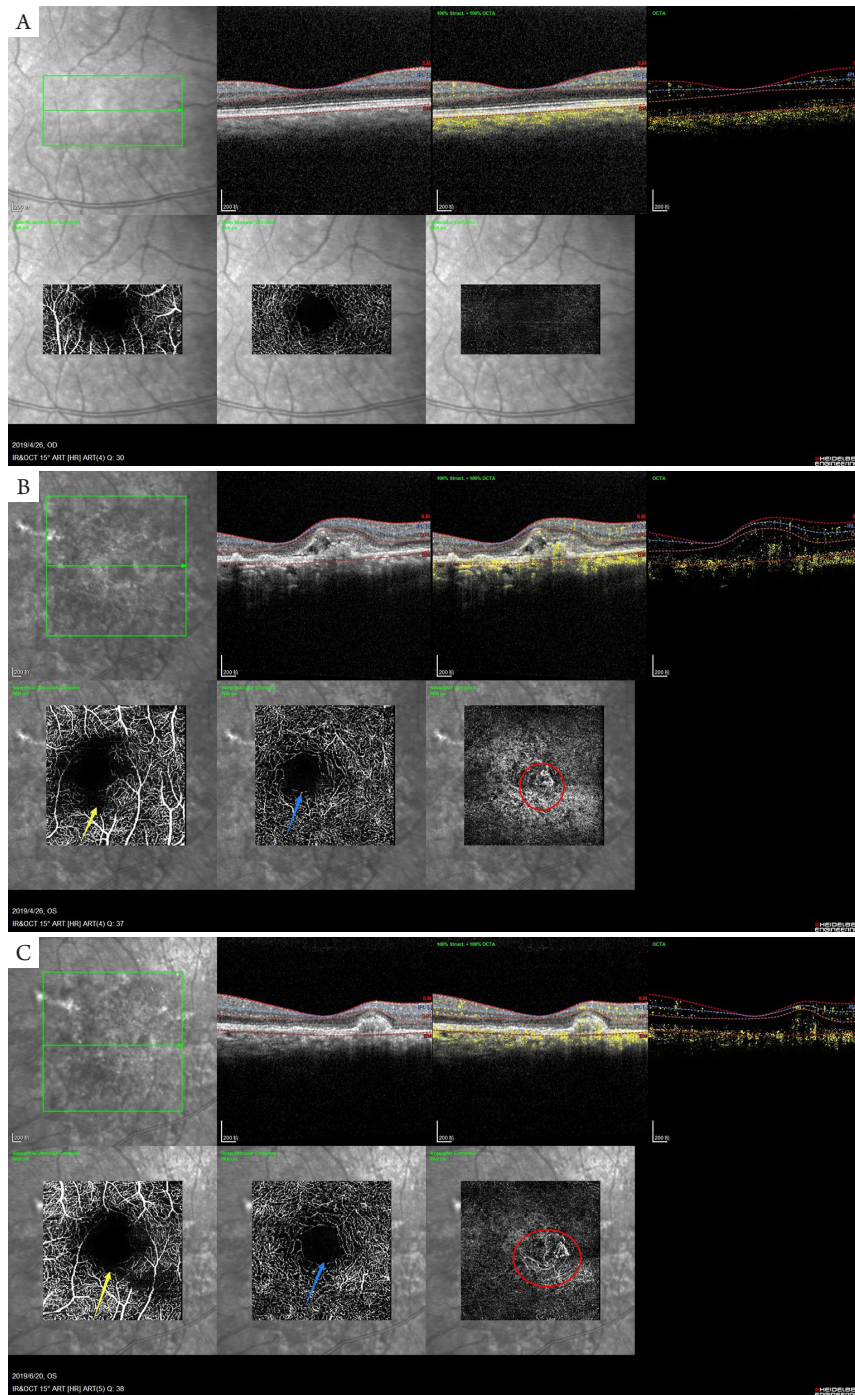


图5 双眼OCTA

Figure 5 OCTA images in bilateral eyes

(A)治疗前右眼OCTA; (B)治疗前左眼OCTA可见浅层(黄色箭头)和深层(蓝色箭头)毛细血管FAZ不规则, 无血管层可见CNV结构(红色圆圈); (C)治疗后左眼OCTA图像。黄色箭头及蓝色箭头显示浅层、深层毛细血管层FAZ规则程度改善, 红色圆圈显示CNV病灶明显缩小。

(A) OCTA images in the right eye before treatment; (B) OCTA images in the left eye before treatment. The FAZ in the superficial complex (yellow arrow) and the deep vascular complex (blue arrow) was irregular. CNV structure (red circle) showed in the avascular complex; (C) OCTA images in the left eye after treatment. The yellow and blue arrow showed the improvement of the regularity of FAZ in the superficial and deep vascular complex. The red circle showed the CNV lesion shrank significantly.

表1 治疗前后OCTA各参数变化

Table 1 Changes of OCTA parameters before and after treatment

眼别	视网膜浅层血流密度/%	视网膜深层血流密度/%	FAZ面积/mm ²	CNV面积/mm ²
治疗前左眼	43.6	45.8	0.231	0.151
治疗后左眼	45.3	48.4	0.272	0.072
右眼	47.9	50.8	0.317	—

2 讨论

CSC大多为自限性疾病,预后良好,部分患者为慢性CSC,病程迁延不愈,造成永久性视力损伤。近年来,文献[1-3]报告CSC合并CNV的发病率在2.0%~15.6%,大部分CSC并发CNV病例为1型CNV,少数为2型CNV,CNV位置可位于中心凹下、旁中心凹和中心凹外。CSC并发CNV的危险因素包括:慢性CSC、女性性别、脉络膜高渗透性^[1]、初始发病时BCVA差、高血压、双层征和眼底彩照上的RPE改变^[3]。CSC-CNV的治疗方法包括PDT、局灶光凝、抗VEGF治疗和联合治疗^[1-3]。国内文献[4-6]报道多为普通激光或光动力学治疗(photodynamic therapy, PDT)治疗CSC后继发的CNV病例,陈青山等^[7]报道CSC-CNV可转化为增厚型脉络膜新生血管病变(pachychoroid neovascularopathy, PNV)或息肉状脉络膜血管性病变(polypoidal choroidal vasculopathy, PCV),其中36%的I型CNV合并CSC可转化为PCV;CSC,PNV和PCV具有一些共同特征,均可表现为黄斑区脉络膜毛细血管扩张、高通透性、脉络膜增厚和浆液性色素上皮脱离(pigment epithelium detachment, PED)。

本病例特点为中年男性,既往无激光治疗病史,通过多模式影像技术诊断为双眼慢性CSC合并左眼CNV,经过1次抗VEGF治疗后CNV病灶缩小,视力明显改善。本病例采用多模式影像技术检查,FFA检查显示患者双眼均存在渗漏点。因CSC患者FFA上可发现不同类型的渗漏点,FFA造影上有时难以鉴别CSC的渗漏点和CNV的渗漏病灶,在不具备ICGA造影条件时,往往难以发现CNV的存在。本例患者在OCTA上发现了FAZ不规则和新生血管结构,因此确诊CNV的存在。在治疗后随访中,通过OCTA和OCT观察到解剖结构的改善。眼底彩照可以显示出黄斑区RPE层不均匀

的色素改变,而炫彩眼底照相则显示了左眼黄斑区略微隆起的病灶,在治疗后可见黄斑区病灶隆起的高度下降。在本病例中,我们利用了多模式影像检查技术中不同技术的特点,总结如下:1)FFA显示视网膜的渗漏病灶,且动态显示渗漏病灶随时间的变化,提示病灶处于活动期;2)眼底彩照可以真实反映病灶的颜色和RPE的改变;3)OCT扫描可观察到病灶的层次、视网膜下液的变化和脉络膜的情况,OCTA可显示病灶区域是否存在新生血管结构,这种结构是在FFA中无法直接观察到的。同时通过Image J软件的帮助,可以在病情随访过程中对CNV病灶大小、FAZ和黄斑中心凹血管密度的变化进行定量分析;4)炫彩照相可以显示病灶的大小和隆起程度。不同的影像检查可以从不同的侧面反映病变的范围、程度或性质,尤其是OCTA可以帮助鉴别FFA中难以确定性质的渗漏病灶,随访中也能直观地显示CNV对治疗的反应情况,我们认为多模式影像技术对CSC合并CNV病例的诊断和随访具有一定的优势,有助于做出准确诊断和随访观察。然而,本病例仅为个案分析,多模式影像诊断技术对CSC合并CNV病例的诊断价值及影像学特征需要将来在更多病例中进一步研究分析。

参考文献

- Shiragami C, Takasago Y, Osaka R, et al. Clinical features of central serous chorioretinopathy with type 1 choroidal neovascularization[J]. *Am J Ophthalmol*, 2018, 193: 80-86.
- Lai TYY, Staurenghi G, Lanzetta P, et al. Efficacy and safety of ranibizumab for the treatment of choroidal neovascularization due to uncommon cause: twelve-month results of the MINERVA study[J]. *Retina*, 2018, 38(8): 1464-1477.
- Lee GI, Kim AY, Kang SW, et al. Risk factors and outcomes of choroidal

- neovascularization secondary to central serous chorioretinopathy[J]. Sci Rep, 2019, 9(1): 3927.
4. 钱彤, 黎晓新. 激光治疗中浆后发生脉络膜新生血管一例[J]. 中国实用眼科杂志, 2008, 26(7): 664.
QIAN Tong, LI Xiaoxin. A case of CNV secondary to CSC after laser treatment[J]. Chinese Journal of Practical Ophthalmology, 2008, 26(7): 664.
 5. 薛秋萍. 激光治疗中心性浆液性脉络膜视网膜病变后发生脉络膜新生血管1例[J]. 实用医学杂志, 2010, 26(15): 2871-2872.
XUE Qiuping. A case of CNV in CSC presented after laser treatment[J]. The Journal of Practical Medicine, 2010, 26(15): 2871-2872.
 6. 苏燕, 李金凤, 郑秀云, 等. 中心性浆液性脉络膜视网膜病变激光治疗后发生脉络膜新生血管二例[J]. 眼科, 2006, 15(1): 71-72.
SU Yan, LI Jinfeng, ZHENG Xiuyun, et al. Two cases of CNV secondary to CSC after laser treatment[J]. Ophthalmology in China, 2006, 15(1): 71-72.
 7. 陈青山, 赵霞, 李志, 等. 中心性浆液性脉络膜视网膜病变转换为PCV和PNV的多模式影像学特征[J]. 中华实验眼科杂志, 2019, 37(1): 30-34.
CHEN Qingshan, ZHAO Xia, LI Zhi, et al. Multimodal imaging characteristics of central serous chorioretinopathy converted to polypoidal choroidal vasculopathy and pachychoroidal neovascularization[J]. Chinese Journal of Experimental Ophthalmology, 2019, 37(1): 30-34.

本文引用: 吴敏, 闵洁, 杨文芝, 盛智超. 多模式影像技术诊断中心性浆液性脉络膜视网膜病变并发脉络膜新生血管1例[J]. 眼科学报, 2020, 35(2): 130-136. doi: 10.3978/j.issn.1000-4432.2020.05.04

Cite this article as: WU Min, MIN Jie, YANG Wenzhi, SHENG Zhichao. Diagnosis of central serous chorioretinopathy complicated with choroidal neovascularization by multi-mode imaging technology: A case report[J]. Yan Ke Xue Bao, 2020, 35(2): 130-136. doi: 10.3978/j.issn.1000-4432.2020.05.04