

doi: 10.3978/j.issn.1000-4432.2020.03.07

View this article at: <http://dx.doi.org/10.3978/j.issn.1000-4432.2020.03.07>

## 先天性视盘小凹合并黄斑劈裂1例

晏颖, 高钺苑, 刘然, 陈晓

(中国人民解放军中部战区总医院眼科, 武汉 430060)

**[摘要]** 视盘小凹是一种很少见的先天性视神经发育异常。视盘小凹所并发的黄斑病变包括黄斑区视网膜劈裂和视网膜脱离, 均是造成患者视力下降的重要原因。关于视盘小凹合并黄斑下积液的来源众说纷纭, 主要有3种学说: 液化的玻璃体、脑脊液外漏及小凹底部血管的渗漏。本文主要报告中国人民解放军中部战区总医院收治的1名35岁的右眼先天性视盘小凹伴黄斑劈裂的女性患者, 手术时行气液交换, 观察有液体自小凹处源源不断涌出的现象, 将引流液进一步行生化分析, 发现与脑脊液成分相似。因此推测视盘小凹合并黄斑下积液来源于脑脊液。

**[关键词]** 先天性; 视盘小凹; 黄斑劈裂; 视网膜下液; 病例讨论

## Congenital optic disc pit with macular retinoschisis: A case report

YAN Ying, GAO Chengyuan, LIU Ran, CHEN Xiao

*(Department of Ophthalmology, General Hospital of Central Theater Command of People's Liberation Army of China, Wuhan 430060, China)*

**Abstract** Optic disc pit is a rare congenital anomaly of the optic disc. Optic disc pit maculopathy, including macular retinoschisis and macular detachment, is the important cause of vision loss in patients. The origin of the subretinal fluid at the area of macula in optic disc pit has not been fully understood. Three different hypotheses have been proposed, liquefied vitreous, cerebrospinal fluid leakage from the subarachnoid space and leakage from blood vessels at the optic disc pit. This article reported a 35-year-old female patient presenting with congenital optic disc pit with macular retinoschisis in her right eye admitted to our hospital. During the air-fluid exchange in vitreoretinal surgery, we found a steady stream of fluid gushing from the optic disc pit. Further biochemical analysis showed that its composition was similar to that of cerebrospinal fluid. Therefore, we prefer the hypothesis that the fluid is derived from the cerebrospinal fluid.

**Keywords** congenital; optic disc pit; macular retinoschisis; subretinal fluid; case report

收稿日期 (Date of reception): 2020-02-16

通信作者 (Corresponding author): 陈晓, Email: 1044768526@qq.com

基金项目 (Foundation item): 湖北省卫生健康委员会科研联合项目 (WJ2019H102)。This work was supported by the Scientific Research Project of Hubei Provincial Health Committee, China (WJ2019H102).

视盘小凹是一种很少见的先天性视神经发育异常, 关于视盘小凹合并黄斑下积液的来源有众多假说, 均未得到明确证实。中国人民解放军中部战区总医院(以下简称我院)收治了1例35岁的右眼先天性视盘小凹伴黄斑劈裂的女性患者, 手术时行气液交换, 在气液交换的过程中, 不断有液体自小凹处涌出, 将引流液行生化分析, 发现其成分与脑脊液类似, 这为小凹下液体来源于脑脊液这一假说提供了进一步的证据。

## 1 临床资料

患者, 女, 35岁, 自觉右眼视力下降伴视物变形2个月, 于2019年10月8日在我院就诊。既往体健。眼科检查: 右眼视力0.1, 矫正不应, 左眼视力1.0, 右眼眼压14 mmHg(1 mmHg=0.133 kPa), 左眼眼压15 mmHg, 双眼眼前节检查未见明显异常, 右眼视网膜平伏, 视乳头颜色正常, 视盘颞侧有一圆形凹陷, 呈青灰色, 直径约为视乳头直径(papillary diameter, PD)的1/5, 有细小血管从凹陷边缘经过, 视盘与黄斑间有一条带状异常区, 黄斑区可见囊样水肿(图1A)。谱域光学

相干层析成像(spectral domain optical coherence tomography, SD-OCT)可见视盘边缘玻璃体牵拉, 呈垂直方向, 视盘颞侧可见视网膜劈裂(图1B), 黄斑劈裂, 呈囊样水肿(图1C)。左眼眼底检查未见异常。诊断: 1)右眼先天性视盘小凹; 2)右眼黄斑劈裂。2019年10月10日于我院行“右眼玻璃体切除+内界膜剥除+无菌空气填充术”, 术中完成玻璃体切除后, 剥除以黄斑中心凹为中心, 半径约1PD范围内的内界膜, 行气液交换, 观察液体自小凹处源源不断涌出(图2)。用23G导管吸取小凹处引流液, 送检验科行生化分析。生化结果(表1)显示: 视盘小凹处引流液与脑脊液成分相似, 其中氯(120.0 mmol/L; 脑脊液参考值: 111~128 mmol/L), 糖(3.00 mmol/L; 脑脊液参考值: 2.5~3.9 mmol/L), 蛋白(0.2 g/L; 脑脊液参考值: 0.15~0.4 g/L)。2019年10月24日于门诊复查, 眼科检查: 右眼矫正视力0.3, 左眼视力1.0, 右眼眼压12 mmHg, 左眼眼压14 mmHg, 双眼眼前节检查未见明显异常, 右眼玻璃体腔空气已吸收(图3A), 视盘边缘玻璃体牵拉已解除(图3B), 黄斑劈裂消失, 水肿较前减轻, 中心凹形态恢复(图3C)。

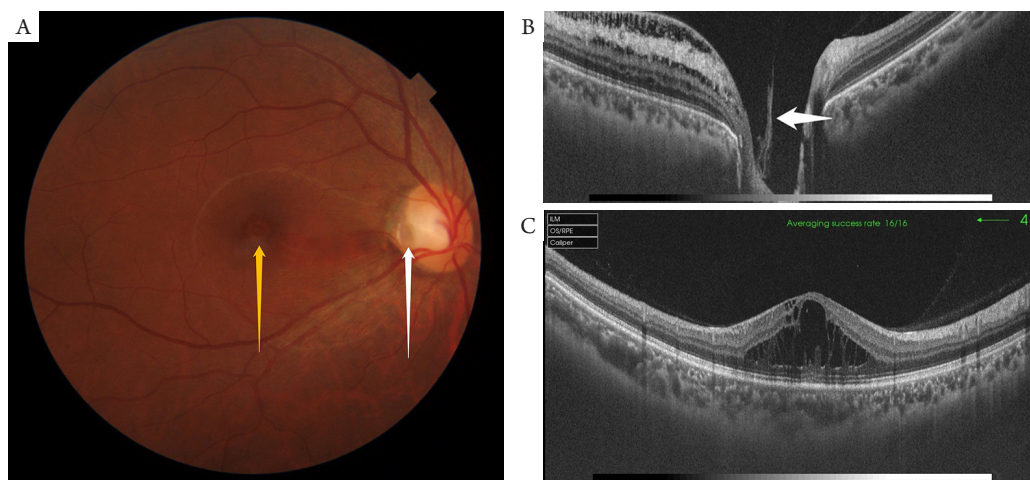


图1 右眼前彩色眼底像及SD-OCT

### Figure 1 Fundus photograph and SD-OCT image of the right eye before the surgical intervention

(A) 视盘颞侧有一圆形凹陷, 呈青灰色, 约1/5 PD(白色箭头), 有细小血管从凹陷边缘经过, 视盘与黄斑间有一条带状异常区, 黄斑区可见囊样水肿(黄色箭头)。(B) 视盘边缘玻璃体牵拉, 呈垂直方向, 视盘颞侧可见视网膜劈裂(白色箭头)。(C) 黄斑劈裂, 呈囊样水肿。

(A) There is a circular depression on the temporal side of the optic disc, which is bluish-gray, about 1/5 PD (white arrow), with small vessels passing through the edge of the depression. There is a banded abnormal area between the optic disc and the macular area, and cystoid macular edema can be seen (yellow arrow). (B) Vitreous body pulling in vertical direction on the edge of the optic disc, retinoschisis can be seen on the temporal side of the optic disc (white arrow). (C) Macular retinoschisis, showing cystoid edema.

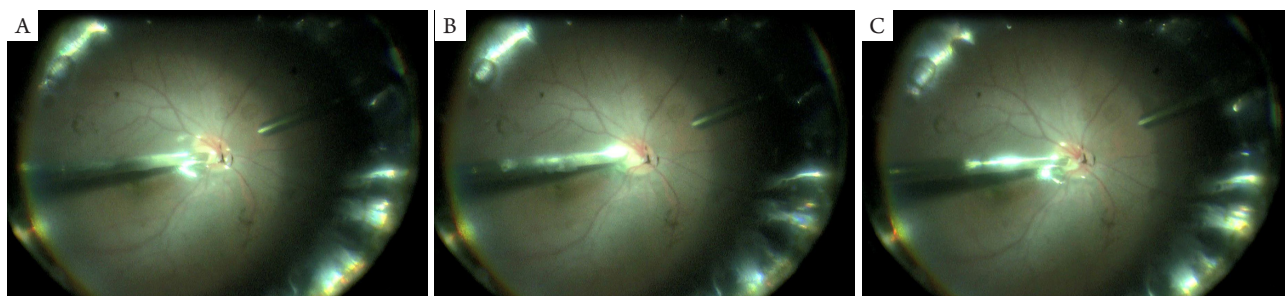


图2 右眼手术录像(按时间帧截图)

Figure 2 Screenshots by frame of the right eye surgery video

(A)进行气液交换;(B)玻璃体腔完全气体填充,视乳头前无液体残留;(C)视盘小凹处液体涌出。

(A) Air-fluid exchange; (B) Complete gas filling in vitreous cavity, no liquid residue in front of the optic papilla; (C) A steady stream of fluid gushing from the optic disc pit.

表1 视盘小凹处引流液生化分析

Table 1 Biochemistry analysis of fluid from the optic disc pit

检验项目	结果	参考值
氯	120.00 mmol/L	111.00~128.00 mmol/L
糖(脑脊液)	3.00 mmol/L	2.50~3.90 mmol/L
蛋白(脑脊液)	0.20 g/L	0.15~0.40 g/L

结果显示: 视盘小凹处引流液与脑脊液成分相似。

The results showed that the drainage fluid at the optic disc recess was similar to that of cerebrospinal fluid.

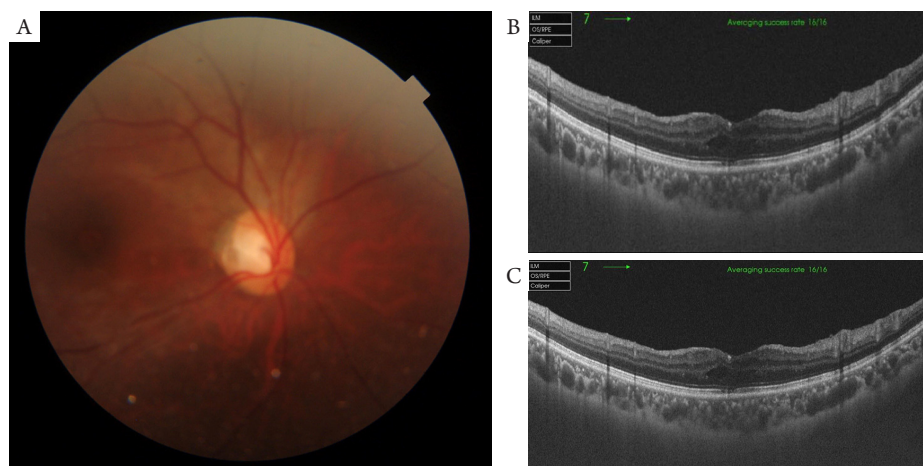


图3 右眼术后彩色眼底像及SD-OCT

Figure 3 Fundus photograph and SD-OCT image of the right eye after the surgical intervention

(A)玻璃体腔空气已吸收,视盘颞侧有一圆形凹陷,黄斑水肿较前减轻;(B)视盘边缘玻璃体牵拉已解除;(C)黄斑劈裂消失,水肿较前减轻,中心凹形态恢复。

(A) The gas in the vitreous cavity has been absorbed, the temporal side of the optic disc has a circular depression, macular edema is any less than before; (B) Vitreous body pulling in vertical direction on the edge of the optic disc has been lifted; (C) Macular retinoschisis has disappeared, edema is any less than before and the fovea configuration has been restored.

## 2 讨论

视盘小凹是一种很少见的先天性视神经发育异常<sup>[1]</sup>, 多为在胚裂过程的异常所致。胚胎约6周, 胚胎生长15 mm, 眼裂面侧融合时胚裂上端的不完全或异常联合造成。通常绝大多数眼组织缺损发生在这个时期<sup>[2]</sup>。视盘小凹所并发的黄斑病变, 包括黄斑区视网膜劈裂和视网膜脱离, 均是造成患者视力下降的重要原因<sup>[3]</sup>。Petersen<sup>[4]</sup>于1958年首先提出黄斑区视网膜下积液与视盘小凹的关系, 其报告的9例视盘小凹的患者中有3例患有视网膜疾病, 均始于黄斑水肿, 而显微镜检查显示: 与视盘小凹同侧的视网膜及脉络膜出现了明显的水肿、血管以及淋巴管的扩张, 而这些变化在另一侧的视网膜中并未被发现。经过半个世纪的研究, 关于视盘小凹合并黄斑下积液的来源众说纷纭, 目前主要有3种学说<sup>[5]</sup>: 液化的玻璃体、脑脊液外漏及小凹底部血管的渗漏。

1) 第一种学说: 来源于液化的玻璃体。有研究<sup>[6-7]</sup>向牧羊犬的玻璃体内注射印度墨水染料, 随后该种染料在视网膜下的空间中被发现。还有研究<sup>[8]</sup>表明: 在视盘有空洞异常的患者中, 气体或硅油会从玻璃体转运到视网膜下间隙, 包括视盘小凹的患者。2) 第二种学说: 来源于脑脊液外漏。有学者<sup>[9]</sup>从4位先天性视盘小凹患者的OCT图像观察到一条低反射性通道, 该通道连接了视网膜裂隙腔和筛板中与视盘小凹相对应的间隙, 证明了视盘小凹中存在的视网膜劈裂与筛板间隙之间的连通性, 支持了脑脊液作为视网膜下液来源的假设。另有研究<sup>[10]</sup>收集了2例视盘小凹患者手术时气液交换置换出的液体, 经过离心及生化分析后发现2份样本的成分均与脑脊液类似。3) 第三种学说: 来源于小凹底部血管的渗漏。研究<sup>[11]</sup>证实: 荧光素血管造影显示视盘小凹性黄斑病变患者的眼睛出现晚期高荧光。

本例报告具有2个临床意义: 一, 本病例观察视盘小凹处有明显玻璃体牵拉, 同时牵拉方向垂直于视盘平面, 这与正常人平行附着的方向是不同的。通过玻璃体切除术松解玻璃体对视盘小凹处的牵拉, 黄斑劈裂得以恢复。这与有些学者<sup>[12]</sup>单纯

进行玻璃体切除术松解玻璃体对视盘及黄斑的牵拉, 并未行激光或气体填充治疗后, 黄斑劈裂及脱离得以恢复的结果是一致的。这在一定程度证实玻璃体牵拉是该病的一个诱因。二, 本病例术中行气液交换时, 自小凹处不断有液体涌出。此时已完成玻璃体切除, 并无液化玻璃体。将术中自视盘小凹处取出的引流液进一步行生化分析, 发现与脑脊液成分相似。因此, 我们更为倾向液体来源为脑脊液这一假说。

## 参考文献

1. Wiethe T. Ein fall von angeborener deformitat der sehnervenpapille[J]. Arch Augenheilkd, 1882, 11: 14.
2. 魏文斌, 陈积中. 眼底病鉴别诊断学[M]. 第1版. 北京: 人民卫生出版社, 2012: 83.  
WEI Wenbin, CHEN Jizhong. Differential diagnosis of fundus ophthalmopathy[M]. 1st ed. Beijing: People's Medical Publishing House, 2012: 83.
3. Qayum S, Sullivan T, Park SC, et al. Structure and clinical significance of central optic disc pits[J]. Ophthalmology, 2013, 120(7): 1415-1422.
4. Petersen HP. Pits or crater like holes in the optic disc[J]. Acta Ophthalmol (Copenh), 1958, 36(3): 435-443.
5. Kalogeropoulos D, Ch'ng SW, Lee R, et al. Optic disc pit maculopathy: a review[J]. Asia Pac J Ophthalmol (Phila), 2019, 8(3): 247-255.
6. Brown GC, Shields JA, Patty BE, et al. Congenital pits of the optic nerve head: I. Experimental studies in collie dogs[J]. Arch Ophthalmol, 1979, 97(7): 1341-1344.
7. Brown GC, Shields JA, Patty BE, et al. Congenital optic pits and serous retinal detachment[J]. Trans Pa Acad Ophthalmol Otolaryngol, 1979, 32(2): 151-154.
8. Dithmar S, Schuett F, Voelcker HE, et al. Delayed sequential occurrence of perfluorodecalin and silicone oil in the subretinal space following retinal detachment surgery in the presence of an optic disc pit[J]. Arch Ophthalmol, 2004, 122(3): 409-411.
9. Gowdar JP, Rajesh B, Giridhar A, et al. An insight into the pathogenesis of optic disc pit-associated maculopathy with enhanced depth imaging[J]. JAMA Ophthalmol, 2015, 133(4): 466-469.
10. Türkçüoğlu P, Taskapan C. The origin of subretinal fluid in optic disc pit maculopathy[J]. Ophthalmic Surg Lasers Imaging Retina, 2016, 47(3): 294-298.

11. Theodossiadis GP, Ladas ID, Panagiotidis DN, et al. Fluorescein and indocyanine green angiographic findings in congenital optic disk pit associated with macular detachment[J]. Retina, 1999, 19(1): 6-11.
12. Skaat A, Moroz I, Moisseiev J. Macular detachment associated with an optic pit: optical coherence tomography patterns and surgical outcomes[J]. Eur J Ophthalmol, 2013, 23(3): 385-393.

本文引用：晏颖, 高毓苑, 刘然, 陈晓. 先天性视盘小凹合并黄斑劈裂1例[J]. 眼科学报, 2020, 35(2): 142-146. doi: 10.3978/j.issn.1000-4432.2020.03.07

**Cite this article as:** YAN Ying, GAO Chengyuan, LIU Ran, CHEN Xiao. Congenital optic disc pit with macular retinoschisis: A case report[J]. Yan Ke Xue Bao, 2020, 35(2): 142-146. doi: 10.3978/j.issn.1000-4432.2020.03.07