



doi: 10.12419/es23090501

View this article at: <https://dx.doi.org/10.12419/es23090501>

· Case Report ·

A novel technique to identify and remove the conjunctival lymphangiectasia using indocyanine green gel

Jingyao Chang(常婧瑶)^{1,2}, Xiaoran Zhang(张潇冉)^{2,3}, Qian Cao(曹谦)², Chunyan Xue(薛春燕)^{1,2,3}

1. School of medicine, Southeast University, Nanjing 210000, China

2. Department of Ophthalmology, Jinling Hospital, Nanjing 210000, China

3. School of medicine, Nanjing University, Nanjing 210000, China

HIGHLIGHTS

- Methodological Innovations: This is the first report introducing a novel technique using indocyanine green gel (ICG gel) for the surgical excision of conjunctival lymphangiectasia (CL).
- Novel Contributions: ICG gel amalgamates the advantages of ICG and Viscoat including its fluorescent color, relatively lymphatic-specific, and viscoelastic properties.
- Implications for Practice: This novel technique can facilitate the identification and complete removal of CL with intact cyst wall, which can minimize the recurrence with little additional tissue damage.

Abstract: In this case report it describes a novel technique using indocyanine green gel for the surgical excision of conjunctival lymphangiectasia (CL). CL was found on the nasal side of left eye in a 50-year-old male. Surgical excision of the entire cystic lesion with an intact cyst wall was completed with the assistance of an indocyanine green (ICG) gel. No sutures were used throughout the entire procedure. Subsequent post operative follow-up was uneventful. Herein, we report a novel technique used to facilitate the identification and complete removal of an intraocular cystic lesion ensuring an intact cyst wall.

Keywords: conjunctival lymphangiectasia; conjunctival cyst; indocyanine green gel; viscoat

Cite this article as: Chang JY, Zhang XR, Cao Q, Xue CY. A novel technique to identify and remove the conjunctival lymphangiectasia using indocyanine green gel. *Eye Science*, 2024, 1(1): 88-92. doi: 10.12419/es23090501

Received date: 2023-09-05; **Accepted date:** 2023-12-26; **Published online:** 2024-03-29

Corresponding author: Chunyan Xue, E-mail: xuechunyan@nju.edu.cn.



Full Text

INTRODUCTION

CL is an uncommon conjunctival lesion that can cause cosmetic concerns and discomfort for patients.^[1] It is crucial to completely remove the whole lesion with an intact cyst wall to avoid recurrence.^[1-3] However, under subconjunctival anesthesia, it can be challenging to distinguish the translucent lesion. Consequently, a larger excision is often performed, involving tissues wider than the actual lesion, which may lead to incomplete removal and additional tissue damage. In this case, we describe a novel technique utilizing ICG gel, which been proved successful in treating CL.

CASE HISTORY

A 50-year-old male reported one-year history with intermittent nasal bulbar redness and irritation in his left eye, and not in the right eye. The topical lubrications was used to relieve the symptomatic. No ocular surgery history was reported. The best corrected visual acuity in both eyes were 1.0/1.0. in the examination. With slit lamp examination, a focal cystic area was found nasally within the bulbar conjunctiva in the left eye (Figure 1a), which was diagnosed as CL in clinical practice. The patient underwent outpatient surgery for CL excision and detailed surgery procedure are described in the following section. Subsequent post operative follow-up was uneventful.

SURGICAL TECHNIQUE FOR CL EXCISION

After employing appropriate aseptic techniques and positioning the blepharostat, surface anesthesia was induced by instilling 1% lidocaine eye drops three

times. A prepared formulation known as ICG gel, a homogeneous amalgamation consisting of 3 drops of ICG solution (5 mg/ml) and 1ml of Viscoat (which contains sodium chondroitin sulfate 4% and sodium hyaluronate 1.65%, produced by Alcon), was utilized^[4]. The ICG gel was then meticulously and gradually injected into the conjunctival cyst using a 1 ml syringe equipped with a 30-gauge needle, exerting appropriate pressure. Injection was discontinued once the cyst appeared sufficiently filled and the ICG gel was uniformly distributed, aiding in easier identification of the focal lesion (see Figure 1b). Subsequently, subconjunctival anesthesia was administered approximately 2 mm away from the cyst, employing a combination of 2% lidocaine and 0.75% bupivacaine. A small incision was made along the border of the focal lesion on the bulbar conjunctiva, followed by a delicate blunt dissection of the surrounding bulbar conjunctiva using a 0.4 mm inclined syringe needle. The distended lesion, along with the intact cyst wall, could be completely dissected away from adjacent tissues. Minimal bleeding was observed during the procedure, and no sutures were employed due to the small incision. To conclude the surgery, 0.3% tobramycin ointment was applied topically prior to patching. A pressure dressing

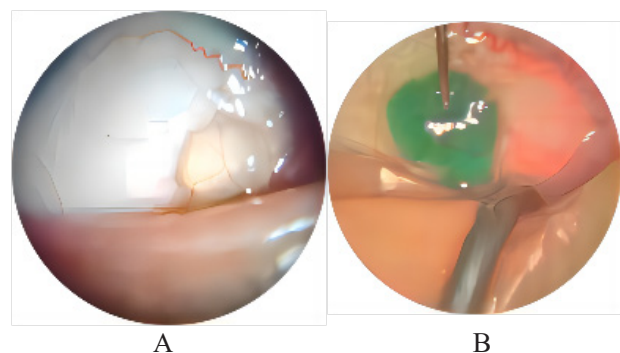


Figure 1 Conjunctival Lymphangiectasia before and after indocyanine green (ICG) gel injection

(A) Conjunctival Lymphangiectasia under slit lamp biomicroscopy; (B) Explicit range of Conjunctival Lymphangiectasia with ICG gel injected and subconjunctival anaesthesia was performed.

was kept in place for 24 hours, and a course of antibiotics was prescribed for topical administration four times daily for a week.

DISCUSSION

The conjunctiva, the eye's most lymphatic-rich tissue, is characterized by subconjunctival lymphatics that develop from nasal lymphatics without involvement of conjunctival lymph nodes.^[1] The dilation of lymphatic vessels within the bulbar conjunctiva arises from the obstruction of local lymphatic flow, likely triggered by trauma, radiotherapy, and various ocular surgeries.^[1] Beyond the common causes, conjunctival lymphangiectasia (CL) is recognized as an ocular manifestation of several systemic diseases.^[1, 5-6]

CL presents in two main forms: diffusely enlarged lymphatics clinically referred to as conjunctivochalasis, and translucent, cystic lesions or a string of pearls appearance resulting from focal or beaded dilation of lymphatic vessels.^[1] Due to its translucent nature and potential coexistence with conjunctivochalasis, CL can only be provisionally diagnosed through direct observation using a slit lamp or through conjunctival fluorescein staining to enhance visualization.^[7] By identifying the precise location of the lesion, a preliminary differentiation can be made between CL and conjunctival epithelial cysts, as the latter primarily occur in the upper part of the conjunctiva.^[1] However, a definitive diagnosis of CL necessitates pathological confirmation post-excision and, if necessary, immunohistochemical staining for D2-40 to differentiate lymphatic endothelium from capillaries.^[1]

Surgical intervention is warranted for individuals experiencing persistent and symptomatic conjunctival lymphangiectasia (CL). However, traditional methods

such as cyst punctures have shown a high recurrence rate, while newer non-excision therapies also carry the risk of relapse.^[1-3] Despite various surgical excision treatments available for CL, none have reported a method to accurately delineate the extent of the lesion during the procedure. The absence of clear demarcation poses challenges in determining the excision range, resulting in inevitable additional tissue damage. Although a prior study employed a mixture of healon and trypan blue solution to delineate conjunctival myxoma, this approach may not be suitable for CL considering its specific properties.^[8]

Indocyanine green (ICG), an FDA-approved fluorescent dye known for its safety and native coloring, has recently found application in lymphography, yielding superior outcomes.^[9-10] Previous research has demonstrated that subconjunctival injection of ICG effectively identifies subconjunctival lymphatics. Compared to trypan blue and fluorescein, ICG produces sharper and more defined images of lymphatic vessels without any leakage due to its larger molecular weight.^[11-12] On the other hand, Viscoat, a viscoelastic substance, exhibits viscosity and cohesion, rendering it an ideal material for sealing puncture sites and maintaining lesion volume. Previous studies have described a combination of ICG and Viscoat as a fluorescent viscoelastic material that amalgamates the advantages of both approaches.^[4] However, to the best of my knowledge, ICG gel has not been applied in CL surgery before.

We choose ICG gel as a staining and bulking agent for surgical excision of CL because of its fluorescent color, relatively lymphatic-specific, and viscoelastic properties. The lymphatic-specific nature of ICG enables the distinction between dilated lymphatic vessels and capillaries due to its greenish color. Besides, the

viscoelastic nature of Viscoat allows for the long-standing distension of the cyst by sealing the puncture site and preventing leakage. By injecting ICG gel into the CL, it enhances lesion visualization and facilitates differentiation from the normal tenon's capsule during the procedure. This well-demarcated lesion enables safer and more precise excision, ensuring complete removal of cyst wall without residual lesions or additional tissue damage. Additionally, ICG gel naturally disappears upon CL removal, minimizing postoperative complications.

In summary, this is the first report advocating for the application of ICG gel injection into conjunctival lymphangiectasia (CL) to streamline surgical procedures. This innovative technique holds the potential to decrease CL recurrence rates while minimizing the extent of additional tissue damage. There are some limitations in this case. To begin with, in this case, we solely rely on clinical diagnosis and lack a definitive pathological diagnosis. Additionally, this article exclusively presents our inventive technique based on a single case of conjunctival lymphangiectasia (CL) with a solitary cystic lesion, thereby limiting its applicability to cases characterized by diffuse lymphatic enlargement. In order to assess and establish this novel technique, further research through larger-scale studies is required for evaluation and standardization.

Correction notice

None

Acknowledgement

None

Author Contributions

(I) Conception and design: Jingyao Chang, Chunyan Xue

(II) Administrative support: Chunyan Xue, Qian Cao

(III) Provision of study materials or patients: Chunyan Xue, Qian Cao

(IV) Collection and assembly of data: Jingyao Chang, Xiaoran Zhang, Qian Cao

(V) Data analysis and interpretation: Jingyao Chang, Xiaoran Zhang

(VI) Manuscript writing: All authors

(VII) Final approval of manuscript: All authors

Funding

None

Conflict of Interests

None of the authors has any conflicts of interest to disclose. All authors have declared in the completed the ICMJE uniform disclosure form.

Patient consent for publication

None

Ethical Statement

This study does not contain any studies with human or animal subjects performed by any of the authors.

Provenance and Peer Review

This article was a standard submission to our journal. The article has undergone peer review with our anonymous review system.

Data Sharing Statement

None

Open Access Statement

This is an Open Access article distributed in accordance with the Creative Commons Attribution-NonCommercial-NoDerivs 4.0 International License (CC BY-NC-ND 4.0), which permits the non-commercial replication and distribution of the article with the strict proviso that no changes or edits are made and the original work is properly cited (including links to both the formal publication through the relevant DOI and the license). See: <https://creativecommons.org/licenses/by-nc-nd/4.0/>.

References

1. Welch J, Srinivasan S, Lyall D, et al. Conjunctival lymphangiectasia: a report of 11 cases and review of literature. *Surv Ophthalmol.* 2012; 57: 136-48. DOI: 10.1016/j.survophthal.2011.08.001.
2. Choi SM, Jin KH, Kim TG. Successful treatment of conjunctival lymphangiectasia accompanied by corneal dellen using a high-frequency radiowave electrosurgical device. *Indian J Ophthalmol.* 2019; 67(3): 409-411. DOI: 10.4103/ijo.IJO_1109_18.
3. Tan JC, Mann S, Coroneo MT. Successful Treatment of Conjunctival Lymphangiectasia With Subconjunctival Injection of Bevacizumab. *Cornea.* 2016; 35(10): 1375-1377. DOI: 10.1097/ICO.0000000000000899.
4. Park J, Lee J, Lee H, et al. Effectiveness of indocyanine green gel in the identification and complete removal of the medial wall of the lacrimal sac during endoscopic endonasal dacryocystorhinostomy. *Can J Ophthalmol.* 2017; 52(5): 494-498. DOI: 10.1016/j.cjco.2017.03.002.
5. Bunod R, Adams D, Cauquil C, et al. Conjunctival lymphangiectasia as a biomarker of severe systemic disease in Ser77Tyr hereditary transthyretin amyloidosis. *Br J Ophthalmol.* 2020; 104(10): 1363-1367. DOI: 10.1136/bjophthalmol-2019-315381.
6. Hayek S, Adam C, Adams D, et al. Conjunctival lymphangiectasia: a novel ocular manifestation of hereditary transthyretin amyloidosis. *Amyloid.* 2019; 26: 94-5. DOI: 10.1080/13506129.2019.1594760.
7. Park ES, Kim MS, Jun I, et al. A Rare Case of Conjunctival Myxoma Initially Misdiagnosed as a Conjunctival Inclusion Cyst. *Korean J Ophthalmol.* 2021; 35(5): 419-420. DOI: 10.3341/kjo.2021.0091.
8. Al-Ghadeer H, Al-Assiri A, Al-Odhaib S, et al. Successful removal of a conjunctival myxoma. *Middle East Afr J Ophthalmol.* 2012 Jul-Sep; 19(3): 352-353. DOI: 10.4103/0974-9233.97968.
9. Mihara M, Hara H, Araki J, et al. Indocyanine green (ICG) lymphography is superior to lymphoscintigraphy for diagnostic imaging of early lymphedema of the upper limbs. *PLoS One.* 2012; 7(6): e38182. DOI: 10.1371/journal.pone.0038182.
10. Koual M, Benoit L, Nguyen-Xuan HT, et al. Diagnostic value of indocyanine green fluorescence guided sentinel lymph node biopsy in vulvar cancer: A systematic review. *Gynecol Oncol.* 2021; 161(2): 436-441. DOI: 10.1016/j.ygyno.2021.01.031.
11. Akiyama G, Saraswathy S, Bogarin T, et al. Functional, structural, and molecular identification of lymphatic outflow from subconjunctival blebs. *Exp Eye Res.* 2020; 196: 108049. DOI: 10.1016/j.exer.2020.108049.
12. Freitas-Neto CA, Costa RA, Kombo N, et al. Subconjunctival indocyanine green identifies lymphatic vessels. *JAMA Ophthalmol.* 2015; 133(1): 102-104. DOI: 10.1001/jamaophthalmol.2014.3944.